

Variability of residual vision in hemianopic subjects

C. Mark Wessinger^{*}, Robert Fendrich, and Michael S. Gazzaniga

Center for Cognitive Neuroscience and Dept. of Psychology, Dartmouth College, Hanover, NH 03755, USA

Received 15 September 1998; revised 23 November 1998; accepted 29 June 1999

Abstract

Using stabilized visual field mapping techniques, seven hemianopic subjects were extensively investigated for residual visual abilities. Isolated islands of detection abilities were demonstrated by four of these subjects. Additional abilities demonstrated within these islands included saccadic and verbal localization, wavelength discrimination, form discrimination, and motion detection. These abilities were also accompanied by low-confidence ratings, and thus have the character of blindsight. It is noteworthy that different subjects demonstrated different abilities at different visual field locations, underscoring the between and within subject variability often observed with blindsight. Furthermore, magnetic resonance images obtained for each subject demonstrated variable sparing of occipital cortex. Such cortical sparing, in conjunction with the behavioral variability, supports the notion that some instances of blindsight are mediated by remnants of the primary visual pathway.

Keywords: Blindsight, hemianopia, stabilized visual field mapping, residual vision, islands of vision

1. Introduction

Partial decussation of the primary visual pathway at the optic chiasm is responsible for hemisphere specific visual field processing, i.e. the left hemisphere processes the right visual field and vice versa. Furthermore, the visual field is also retinotopically organized such that portions of the visual field imaged by the central retina are processed by posterior aspects of primary visual cortex, and the peripheral visual field imaged in the periphery of the retina is processed at more anterior locations within V1. This retinotopic organization is maintained in several visual association areas [13]. It is well documented that partial damage to the primary visual pathway results in corresponding areas of blindness within the visual field [16,18]. Generally these field defects are considered permanent and absolute, though with specific training designed

to stimulate the visual field some patients have demonstrated an increase in the area of phenomenal vision [20,22,23,42].

There is also a large body of research devoted to understanding reports of non-phenomenal vision within a field defect or “blindsight”. Under special testing conditions some subjects demonstrate the ability to respond correctly to stimuli placed within their field defect, all the while denying any awareness of the stimuli [36]. This is an extremely amazing phenomenon – visual stimuli that subjects deny seeing can, in fact, actually influence their behavior!

Given that the subjects’ phenomenal blindness is a result of damage to the primary pathway it seems reasonable to hypothesize that blindsight is mediated by one of the many secondary visual pathways [9]. The two most often invoked pathways are the retinotectal and the geniculostriate pathways. An alternative explanation is based on surviving remnants of the primary visual pathway [7,8,14,40].

Regardless of the pathway, blindsight has proven quite rare and not always easily demonstrable. Group studies show blindsight is reliably demonstrated in only about 20 % of the

^{*} Correspondence to: C. Mark Wessinger, Center for Cognitive Neuroscience and Department of Psychology, HB 6162 Silsby Hall, Dartmouth College, Hanover, NH 03755, USA; Tel.: 603-646-0279; Fax: 603-646-1181; E-mail: wessinger@dartmouth.edu

subjects tested. Marzi and colleagues [26], using reaction time facilitation as a measure, found evidence of blindsight in four of 20 patients. Blythe and colleagues [6] report reliable target localization within a field defect in five of 25 patients. Hess and Pointer [15] report a failure to demonstrate blindsight in three subjects presented with sine wave gratings in their field defects. Interestingly, one of these subjects, Case GY has repeatedly demonstrated blindsight abilities when sufficiently large stimuli are used [38] and occasionally demonstrates vision with awareness when sufficiently large, bright and fast moving stimuli are used [3]. Holtzman [17] also reports being unable to find blindsight abilities in a patient with a homonymous hemianopia subsequent to surgical resection of an arteriovenous malformation (a history very similar to case DB who has been the subject of extensive blindsight investigations including a monograph describing the phenomenon, see [36]). The MRI of Holtzmann's subject revealed an occipital lesion which spared the tectal and extrastriate regions. This subject was able to localize targets in her seeing visual field, demonstrating she could understand and perform the required task. However, she was unable to perform the same task within her field defect, and thus, did not demonstrate blindsight. Overall, there appears to be quite a bit of between and within subject variability inherent to the blindsight literature. It was this variability that prompted the series of studies summarized below. Portions of these data have previously been reported elsewhere [14,40].

2. Methods

2.1. Subjects

These studies required participation of patients with dense hemianopia due to chronic, striate cortex lesions subsequent to posterior cerebral artery infarction or occipital surgical ablation. All participants provided informed consent in accord with the guidelines established by Institutional Review Boards and were paid for their participation. Subjects were informed that the nature of the study was to investigate their areas of blindness with the hope of learning more about the nature of the visual system.

CLT is a 56-year-old male who suffered a right posterior cerebral artery stroke in 1987. This stroke produced a dense left homonymous hemianopia, with some sparing in the central portion of the left inferior visual quadrant (quadrant macular sparing).

CN is a 68-year-old male who incurred a left posterior cerebral artery stroke in 1991. This stroke produced a dense right homonymous hemianopia, with some sparing in the central portion of the right inferior visual quadrant.

EH is a 34-year-old male who in 1989 suffered a left posterior cerebral artery stroke subsequent to resection of a low grade astrocytoma in the left inferior occipital lobe. This stroke produced a clinical dense right homonymous hemianopia, without central sparing.

FN is a 57 year-old male who suffered bilateral posterior cerebral artery infarcts in 1988 resulting in complete blind-

ness and disorientation. The visual deficits improved over the next few weeks, stabilizing after about one year. FN currently demonstrates a left homonymous hemianopia and a superior right homonymous scotoma.

FS is a 68 year-old female who incurred a myocardial infarction in 1991 accompanied by disorientation and a right hemiparesis. Computed Tomography revealed a large left temporal-occipital intracerebral bleed which was subsequently evacuated. Thereafter, FS was found to be aphasic, and have a dense right homonymous hemianopia. Following rehabilitation, her hemiparesis has nearly resolved, and the aphasia partially resolved. However, she continues to have a dense right homonymous hemianopia.

JC is a 56 year-old female who has been aware of a left hemiatrophy and mild weakness since childhood. She has a dense left homonymous hemianopia not documented until a seizure in 1974. Seizures are now controlled with Depakote. Otherwise, sensation is intact bilaterally, though responses to stimuli on the left are slowed. It appears that JC incurred an intrauterine right posterior cerebral artery infarct resulting in a right hemisphere perinatal cyst.

TAB is a 22-year-old male who underwent resection of a right parieto-occipital arteriovenous malformation in 1981. Subsequent to surgery he demonstrated a left homonymous hemianopia, with patchy central sparing.

2.2. Equipment

For all experiments, stimuli were generated with a Macintosh IIfx computer and displayed on a Macintosh color monitor. Subject's eye motions were monitored with a double Purkinje image eyetracker [12], and the stimulus displays retinally stabilized with a mirror deflector system [11] attached to the eyetracker. This ability to retinally stabilize stimuli makes possible extended and repetitive stimulus presentations to known retinal positions. Subjects viewed the Macintosh display with their right eye through the stabilizer lens at an effective viewing distance of 57 cm. Viewing was right eye monocular because the double purkinje image eyetracker monitors the right eye and the stabilized image could only be viewed by that eye. The left eye was patched.

2.3. General procedures

In descriptions of the testing procedures, reference is frequently made to a patient's 'blind' and 'seeing' field: 'blind' field refers to the regions within a scotoma defined by conventional perimetry; while 'seeing' field refers to regions outside the scotoma. Generally, different field locations are described in terms of degrees of visual angle from fixation using Cartesian coordinates. For example a location described as (0°, 0°) is centered at fixation, (−15°, −6°) describes a location centered 15° left of and 6° below fixation.

Initial testing involved stabilized field mapping. Saccadic and verbal localization, wavelength discrimination, form discrimination, and movement discrimination analyses were also conducted when practical and possible. The manner in

which this testing was carried out depended upon the distribution of residual detection abilities revealed by the initial stabilized field mapping. The details of these procedures were adjusted to suit the special requirements of each subject.

Forced choice testing methods were used to help alleviate criterion effects, and whenever possible interval 2 alternative forced choice (i2afc) techniques were used. Such forced choice techniques are useful because they can substantially reduce (though not necessarily eliminate) subjective criterion effects [25]. Since we were investigating residual visual abilities within field defects it was necessary to present the majority of the stimuli where patients are clinically blind. With forced choice techniques, subjects must respond on every trial, even when the stimuli are not seen. Subjects were instructed to guess when necessary. When practical, confidence values (cv) were obtained on a trial by trial basis to assess the extent to which patients were aware of the target presentations. A five point scale was used: subjects were instructed to report 1 when their response was a complete guess, 2 when they had a feeling or intuition that influenced their response, 3 when they felt they may have seen something in one of the intervals, 4 when they saw a portion of the stimulus or 5 if they clearly saw when the stimulus was presented. This range of confidence values enabled us to obtain a scaled value that was presumed to relate to a subject's level of awareness. If a subject believed they just were guessing (cv = 1), but performed greater than chance, then it is reasonable to conclude they were exhibiting blindsight. Unless otherwise stated, statistical significance was assessed with a binomial test (normal approximation) and subjected to a Bonferonni correction for multiple tests when appropriate.

Several experimental conditions were controlled in order to maximize sensitivity. Testing was carried out in a darkened room since Bender and Krieger [4] demonstrated residual vision within perimetrically defined blind regions when testing was performed in almost total darkness, although this residual vision was not evident if testing was performed in a lighted environment. Additionally, on most of our tests, stimuli were flashed several times during each presentation. This was done since patients with damage to visual cortex sometimes report the ability to detect flashed or moving objects, but not stationary objects [30]. Unless otherwise noted, black stimuli ($<0.1 \text{ cd/m}^2$) were presented on a gray (10 cd/m^2) background in order to reduce possible artifacts due to light scatter, which is often associated with bright stimuli on a dark background [7].

During testing, a fixation point was superimposed on the stabilized image with a beam-splitter in order to provide a fixation anchor. This was necessary to eliminate open loop wander of the eyes, a phenomenon encountered when subjects view stabilized images [27]. An oscilloscope display allowed the experimenter to monitor the subject's fixation position relative to this point. This arrangement allowed the periodic correction of any offsets that may have appeared in

the eyetracker outputs due to small changes in head position that occurred during the course of testing. Eye position inaccuracies due to head movements were generally less than $15'$ of arc.

2.4. Stabilized visual field mapping

Initially, dense stabilized mapping of the blind field for each subject was conducted to explore the boundaries of the field defect and to probe for areas of residual detection. Standard interstimulus spacing of 6° used in clinical perimetry has been shown to miss small scotomas that were subsequently detected when a smaller interstimulus spacing of 1° or 2° was used [34]. It is reasonable to assume the converse: that standard 6° spacing may miss some islands of preserved function, which may be detected with a finer grid. Therefore, a dense grid of multiple test locations was employed. Testing was conducted with a matrix consisting of 24 to 68 locations. Within each session, a subset of the matrix was tested. Such subsets ranged from 5 to 14 locations. Complete matrices ranged in size from 12.5° to 17.5° horizontally, and 9.3° to 11.5° vertically.

Interval two alternative forced choice (i2afc) methodology was employed to reduce possible criterion effects. On each trial, audible tones defined two successive 600 msec intervals. During one of these intervals, a stimulus was flashed 3 times (96 msec on, 96 msec off). At the end of the second interval, the subject was signaled by a tone to indicate which interval contained the stimulus presentation. Subjects either responded verbally or with a button press, whichever they preferred. Subjects CLT and CN were tested with 1° black circles (see Figure 1a). All others were tested with 2.33° black squares (see Figures 2a, 3a, 4a).

2.5. Subsequent testing

Following the initial stabilized visual field mapping, a series of additional tests (detailed below) were performed. When possible, such further testing was carried out both within regions demonstrating residual visual detection, and other blind field locations in order to assess the character and spatial distribution of abilities throughout the field defect.

2.6. Micromapping

Visual field locations in which the initial stabilized field mapping revealed evidence of surviving visual function were subsequently mapped in greater detail. This procedure entails presenting a matrix of smaller stimuli centered at the location of interest, and is designed to obtain a more precise determination of the size of the area of residual detection. One of two stimulus configurations was used. In one (used with CLT), a 3 by 3 matrix of locations was tested using 1° diameter black stimuli separated by $20'$ of arc covering in total a square area of $3^\circ 40'$. The other configuration (used with JC and FN) consisted of a 2 by 2 matrix of $70'$ of arc contiguous squares covering a 2.33° square area with a 5^{th} stimulus centered within the area of interest. Again, stimuli were presented using an i2afc paradigm as described above.

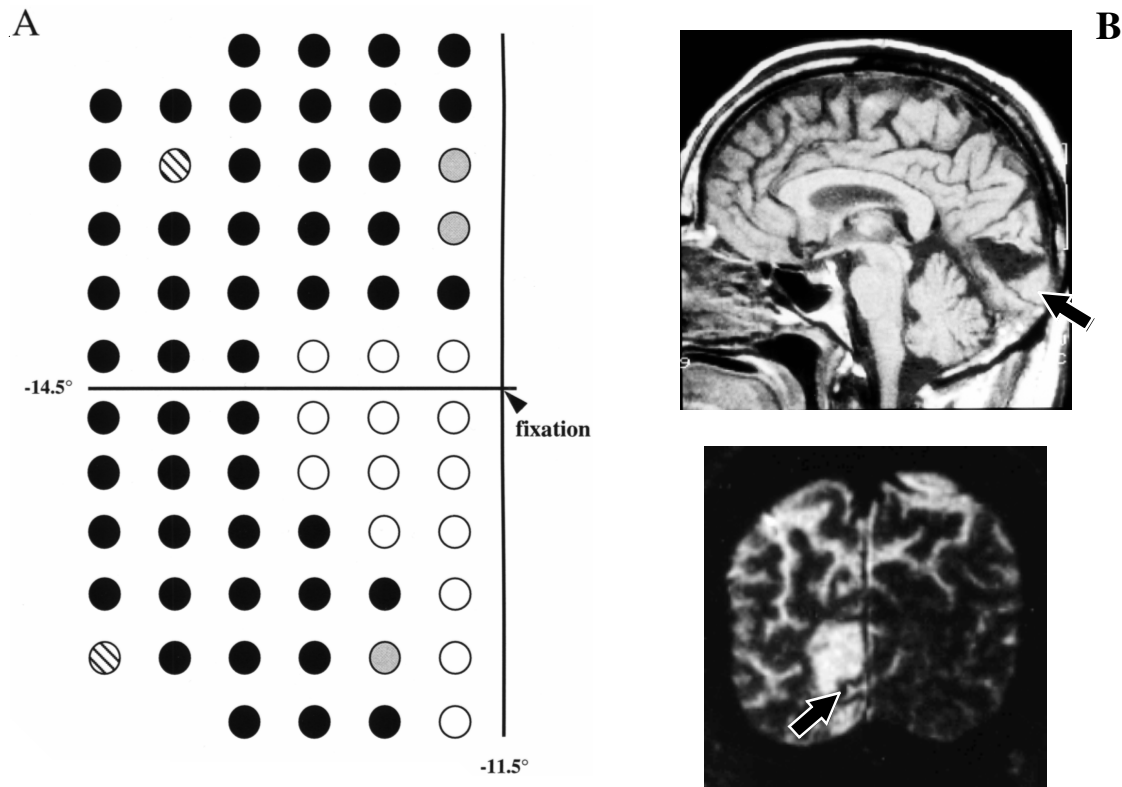


Fig. 1. (A) Schematic representations of stabilized field mapping results for CLT. Each circle represents a different location tested using 1° black circles as described in the methods. Blind locations are shown in black, regions of phenomenal vision with full awareness are white, regions of phenomenal vision with reduced awareness are gray, islands of blindsight are striped. (B) Representative magnetic resonance images showing the lesioned area, as well as cortical sparing (indicated with arrows) in the area of the calcarine cortex. The upper image is a T1-weighted midsagittal image through CLT's right hemisphere, the lower image is a T2-weighted coronal image through CLT's occipital lobe displayed in standard radiological convention with the left hemisphere on the right.

2.7. Localization with saccades

Localization of stimuli with saccades is a frequently reported blindsight ability, and is often interpreted as supporting retinotectal mediation [1,28]. To assess this ability in our subjects, a stabilized stimulus was flashed at one of several locations in the subject's blind or seeing field. The exact locations for each subject are presented with each case description. The saccadic target consisted of either a black 1° diameter circle or a 2.3° square, which was flashed 3 times for 100 msec. Stabilization insured that all three flashes were delivered to a constant retinal position. After the presentations, a tone sounded signaling the subject to make a saccade towards the stimulus. Subjects were informed that a stimulus would be presented on every trial, and were instructed to respond on every trial. Eye position records were collected from the onset of the target until 2 seconds after the signal to saccade, and stored for subsequent analysis. Presentations to seeing areas provided baseline data on the subject's ability to perform the task. For two subjects (FN and JC), blank trials without any stimulus were used to assess the subject's saccadic bias in the absence of any signal. Eye records were analyzed by displaying the eye trace on an oscilloscope and recording the horizontal and vertical eye movement directions. Trials were considered correct if a saccade was directed towards the quadrant that was stimulated. Percent correct per-

formance was then compared to performance at established blind locations or a subject's saccadic bias assessed by the blank trials.

2.8. Localization by verbal report

A second localization task required verbal judgments. A 1° or 2° black circle was presented in a patient's blind field concurrently with an arrow in their seeing field. The circle was presented at one of six blind field locations separated vertically by several degrees. The arrow pointed horizontally toward the blind field, and was vertically aligned with one of the test locations. On each trial, the circle flashed 3 times during a tone delimited 600 msec interval while the arrow remained steadily visible. The subject's task was to report if the arrow and circle were aligned. To assess the ability of the subject to perform the task, control trials were conducted in which both the arrow and circle were presented within the subject's area of macular sparing.

2.9. Wavelength discrimination

It has been reported that some hemianopic patients have the ability to discriminate wavelength in their blind field [9,32,33]. These results have been interpreted as evidence of a geniculo-extrastriate involvement in blindsight due to the putative absence of wavelength sensitivity within the retino-

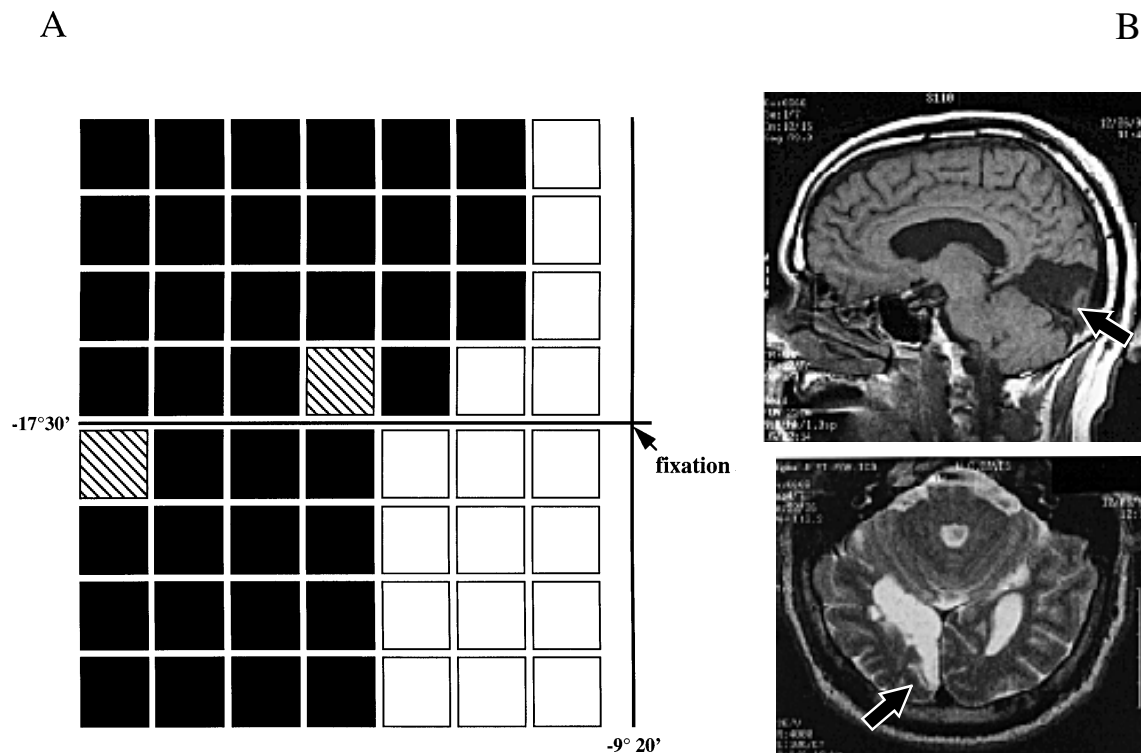


Fig. 2. (A) Schematic representations of stabilized field mapping results for FN. Each square represents a different location tested using 2.33° black squares as described in the methods. Blind locations are shown in black, regions of phenomenal vision with full awareness are white, islands of blindsight are striped. (B) Representative magnetic resonance images showing the lesioned area, as well as cortical sparing (indicated with arrows) in the area of the calcarine cortex. The upper image is a T1-weighted midsagittal image through FN's right hemisphere, the lower image is a T2-weighted axial image through FN's occipital lobe displayed in standard radiological convention with the left hemisphere on the right.

tectal pathway [32]. Additional evidence is supplied by the fact that the majority of surviving retinal ganglion cells following cortical damage are primate beta ganglion cells [10,41]. The survival of these ganglion cells is believed to be maintained by geniculo-extrastriate projections [9]. To evaluate their wavelength discrimination we tested the subject's ability to discriminate red versus green stimuli. Isoluminant stimuli were used so that luminance cues could not aid the discrimination. The stimuli were set to isoluminance with respect to each other and the background using a flicker nulling technique [35] in the patient's seeing field. The procedure involved manipulating the luminance of two rapidly alternating stimuli until the percept of flicker was attenuated. Since wavelength information is presumed to be carried by slow, sustained parvocellular channels and luminance information by fast, transient magnocellular pathways [24] the percept of flicker diminishes when the luminances are equated. As with the initial stabilized field mapping, i2afc methodology was employed. Tones defined two 600 msec test intervals, and the red stimulus was flashed during one interval and the green flashed during the other. Subjects were required to indicate during which interval the red stimulus flashed.

2.10. Form discrimination

The ability of hemianopic subjects to discriminate simple forms, has been reported [36,39], though such data have

been subsequently re-interpreted as demonstrations of orientation discrimination abilities [37]. To assess such abilities in our subjects, simple forms differing in their orientation were used. The stimuli consisted of a square and a diamond (the square rotated 45°). On each trial either a square or diamond flashed during a 600 msec tone delimited interval. Subjects were required to indicate which stimulus had been presented. The square and diamond were both presented on one-half of the trials so that chance performance was 50 %.

2.11. Motion detection

An ability to detect kinetic versus static stimuli placed within a field defect was documented early in the 19th century. Riddoch [30] systematically charted visual fields using moving stimuli and compared them to visual fields obtained using static stimuli and demonstrated considerable sparing of motion detection abilities in the absence of static detection abilities. This effect is referred to as statokinetic dissociation or the Riddoch effect. The motion perception that Riddoch describes often preceded recovery of form and color discrimination abilities, suggesting motion detection provides the earliest indication of recovering vision. There have been a few recent demonstrations of motion detection associated with investigations of blindsight. Barbur et al. [2] demonstrated subject G. is capable of detecting motion and discriminating its direction. Subsequently, subjects GY (G.),

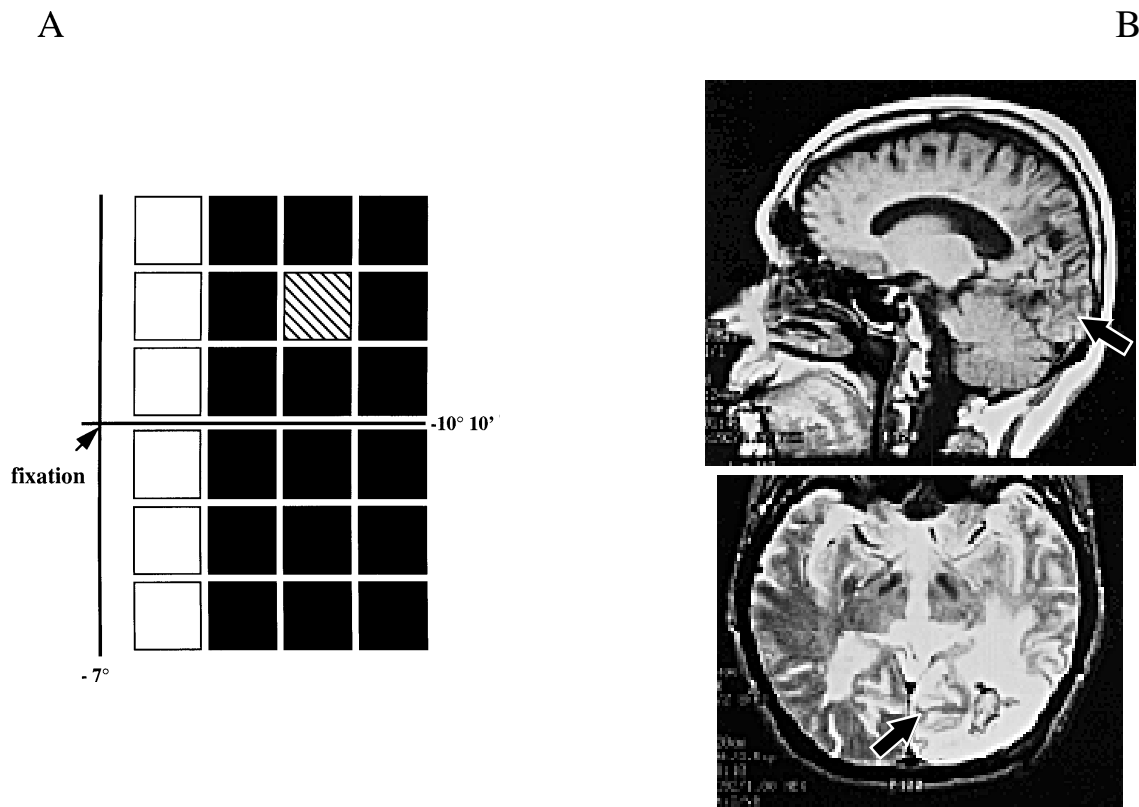


Fig. 3. (A) Schematic representations of stabilized field mapping results for FS. Each square represents a different location tested using 2.33° black squares as described in the methods. Blind locations are shown in black, regions of phenomenal vision with full awareness are white, the island of blindsight is striped. (B) Representative magnetic resonance images showing the lesioned area, as well as cortical sparing (indicated with arrows). The upper image is a T1-weighted midsagittal image through FS's left hemisphere, the lower image is a T2-weighted axial image through FS's occipital lobe displayed in standard radiological convention with the left hemisphere on the right.

and RC both demonstrated motion detection abilities in the absence of object discrimination abilities [5]. Recently, in a PET ^{15}O study, functional activation of the putative human homologue of area MT has been reported in subject GY. The discrimination of motion has also been reported in the blind field of some hemispherectomized patients [29]. Three subjects who had undergone resection of one entire hemisphere demonstrated the ability to detect moving versus stationary sinusoidal gratings, although these subjects are not able to discriminate direction of motion. The task required the subject to choose during which of two tone delimited one second intervals a rightward scrolling grating appeared. The scrolling speed was $3.7^\circ/\text{s}$. An identical, non-scrolling grating was presented in the other interval.

3. Results

CLT: Stabilized visual field mapping was performed using 1° black circles arranged in a grid of 68 points separated 1.5° horizontally and 1° vertically with the medial edge of the grid beginning 1° from the vertical meridian (see Fig. 1A). The region tested in the blind left visual field extended laterally to -15° and superiorly/inferiorly to $\pm 11.5^\circ$. Stimuli were reliably detected -7° lateral, 1.5° superior and

-3.5° inferior to fixation and along the vertical meridian inferiorly to -11.5° . The most notable finding was a region of above chance performance (65 %; $n = 166$; $z = 3.08$; $p < 0.00005$) centered at -11.5° , 7° within CLT's scotoma. Since this region of vision was surrounded by areas of blindness we refer to it as an 'island' of vision. Furthermore, performance at this location was in the absence of awareness, thus has the character of blindsight.

Micromapping of CLT's island of vision was performed using a three by three grid of 1° black circles as described above. Performance significantly greater than chance was observed at the central location (71 %; $n = 66$; $z = 3.32$; $p < 0.001$) and marginally greater than chance at two of the inferior locations (62 %; $n = 66$; $z = 1.85$; $p < 0.06$). This pattern of results indicates the size of the area of detection is not greater than 2° square.

Interestingly, CLT was only successful using 1° stimuli for the form discrimination task (65 %, $n = 288$; $z = 11.84$; $p < 0.001$). When a 2° stimulus was used CLT's performance did not differ from chance (47 %; $n = 72$). CLT also successfully performed the wavelength tasks at his island of vision (63 %; $n = 126$; $z = 2.76$; $p < 0.001$), but was unable to perform saccadic localization, verbal localization, or motion detection tasks at his island.

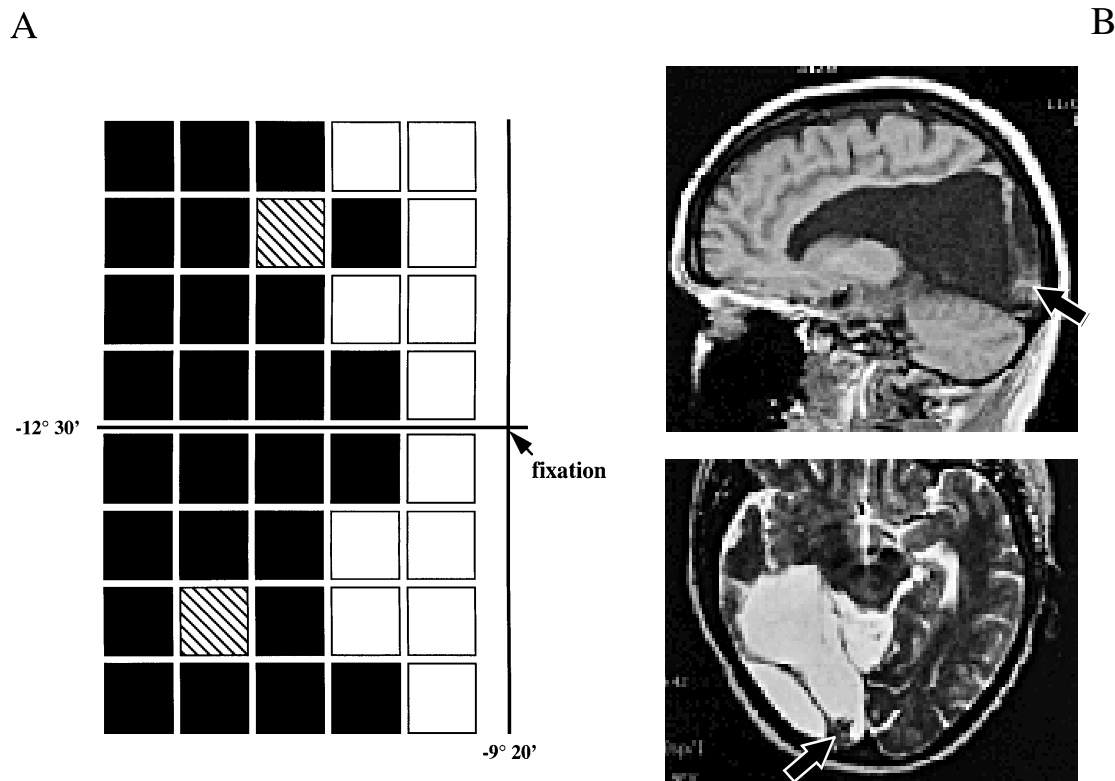


Fig. 4. (A) Schematic representations of stabilized field mapping results for JC. Each square represents a different location tested using 2.33° black squares as described in the methods. Blind locations are shown in black, regions of phenomenal vision with full awareness are white, islands of blindsight are striped. (B) Representative magnetic resonance images showing the lesioned area, as well as cortical sparing (indicated with arrows). The upper image is a T1-weighted midsagittal image through JC's right hemisphere, the lower image is a T2-weighted axial image through the area corresponding to the occipital lobe and is displayed in standard radiological convention with the left hemisphere on the right. Note what appears to be a strip of residual tissue within the depths of the lesioned area.

CN: Stabilized field mapping was performed using 1° black circles 40 locations covering 12.5° (horizontal) by 20° (vertical) within CN's right visual field. No isolated areas of residual detection were found within the field defect. However, we did find a small band with residual detection along the vertical meridian. This band is consistent with CN's clinical perimetry. For personal reasons, CN declined to continue further testing once the stabilized field mapping was completed.

EH: Stabilized field mapping was conducted using 2.33° stimuli comprising a contiguous grid of 44 test locations. The grid extended $14^\circ 50'$ laterally and $\pm 9^\circ 20'$ superiorly/inferiorly into EH's blind right visual field. Performance was 97 % or above at all seeing left visual field locations. EH demonstrated above chance detection along the vertical meridian (perfect performance in the first column superiorly and ≥ 81 % inferiorly), but no isolated areas of residual detection were identified, thus microperimetry was not performed. In the absence of any isolated islands of vision, four locations within EH's field defect, two in the superior and two in the inferior field, were chosen as additional test locations. To confirm task understanding, an additional test location within EH's seeing left visual field was tested. Saccadic localization was perfect ($n = 52$) in the seeing field location, but did not differ from chance at any of the four blind field locations. EH

demonstrated verbal localization abilities (≥ 92 %) along the vertical meridian, but was at chance at more peripheral locations within his blind field (≤ 58 %). EH was also unable to perform the wavelength discrimination (≤ 55 %, $n = 48$), form discrimination (small stimulus performance range: 38 % to 55 %; large stimulus: 43 % to 58 %; $n = 40$ for each size and each of four locations tested), or motion detection (≤ 53 %; $n = 48$) tasks within his blind field.

FN: Stabilized field mapping using 2.33° square stimuli was employed. Fifty-six contiguous locations were tested covering an area extending $-17^\circ 10'$ laterally and $\pm 9^\circ 20'$ superiorly/inferiorly into FN's blind left visual field (see Fig. 2A). FN demonstrated phenomenal detection abilities in his impaired left visual field along the vertical meridian, extending out as far laterally as $-5^\circ 30'$ and $-7^\circ 50'$ in the superior and inferior quadrants, respectively. In addition, two locations of above chance detection with minimal awareness were found. One is contiguous to regions of phenomenal vision, centered 9° lateral and $1^\circ 10'$ superior to fixation (67 %, $n = 192$, $z = 4.54$, $p < 0.001$) and is referred to as the 'upper island'; the other is isolated within FN's field defect, centered 16° lateral and $1^\circ 10'$ inferior to fixation (68 %, $n = 90$, $z = 3.27$, $p < 0.001$) and is referred to as the 'lower island'. Confidence values at these locations (1.48 and 1.11, respec-

tively) did not differ from the average confidence values for locations without detection ($cv = 1.3$)

Micromapping was performed using the grid of 70' of arc squares as described above. At the lower island, FN performed above chance at two of the five locations, suggesting the island of function is localized to the upper right quadrant of this region. However at the upper island, which is contiguous with regions of awareness, no localized spots of detection were found, suggesting that detection at this location required stimulation of a relatively large retinal area. FN successfully performed the saccadic localization task at both his up and down islands, but was only able to verbally localize stimuli at his upper island. Interestingly, FN was also marginally successful on the verbal localization task at the lower visual field control location and the saccadic localization task at the upper visual control location. Additionally, FN successfully performed the motion detection task at both islands of residual detection. Conversely, FN was unable to perform the wavelength or form discrimination tasks at either island.

FS: Using 2.33° square stimuli, 24 contiguous locations were tested within her blind field, extending laterally to 10°10' and superiorly/inferiorly to $\pm 7^\circ$ (see Fig. 3A). Performance was greater than 96 % correct in the left visual field. In accord with clinical perimetry, sparing was found parafoveally within the field defect along the vertical meridian. In addition, an island of above chance performance was found (67 %, $n = 96$, $z = 3.16$, $p < 0.002$), centered 6°40' to the right of and 3°30' above fixation, surrounded by areas of chance detection. Confidence values were not collected, but informal remarks made by the subject indicate she was not aware of stimuli presented at this island, although she was aware of right field stimuli presented near the vertical meridian. FS chose not to continue testing beyond the initial stabilized field mapping.

JC: Using 2.33° stimuli, 40 contiguous locations within JC's blind field were tested. The grid extended -12.5° laterally and $\pm 9.3^\circ$ superiorly/inferiorly into JC's blind left visual field (see Fig. 4A). Performance was 88 % or greater at all right field locations. A band of above chance detection performance was found along the vertical meridian extending as far as 6° into her blind field at some locations. Similar to FN, two isolated areas of above chance detection were found at different locations in her blind field. Both are completely surrounded by areas of chance detection. A superior field location is centered 6°40' lateral and 5°50' above to fixation and will be referred to as the upper-island (66 %, $n = 122$; $z = 3.35$; $p < 0.0008$); the other island is centered 9° lateral and 5°50' below fixation and will be referred to as lower-island (72 %, $n = 108$; $z = 4.33$; $p < 0.0001$). Detection occurred at both these locations without conscious awareness ($cv = 1.23$ and 1.19, for the upper-island and lower-island respectively). Since several months had lapsed between the time of the initial demonstration of islands of detection and the subsequent demonstration of residual visual abilities the islands of detection were re-confirmed. Performance was

still significantly above chance at both islands: upper-island = (63 %; $n = 48$; $z = 2.25$; $p < 0.03$); lower-island = (69 %; $n = 48$; $z = 3.47$; $p < 0.001$).

Micromapping using the grid of 70' of arc squares arranged as described above revealed isolated 'hot-spots' of detection within each island. At the lower-island above chance detection occurred (72 %; $n = 60$; $z = 3.23$; $p < 0.002$) at the center of the stimulus matrix. At the upper-island above chance detection occurred in the lower right corner of the matrix (64 %; $n = 60$; $z = 2.27$; $p < 0.03$). JC successfully performed both the wavelength discrimination task (61 %; $n = 90$; $z = 2.00$; $p < 0.05$) and the saccadic localization task (60 %; $n = 119$; $z = 2.01$; $p < 0.05$) at the lower island, but not the upper-island. Her performance on all other tasks within the battery (verbal localization, form discrimination, and motion detection) was at chance at both islands. Interestingly, JC was also able to perform the saccadic localization task at the lower visual field control location as well (64 %; $n = 116$; $z = 2.87$; $p < 0.005$).

TAB: Stabilized mapping was performed using 2.33° contiguous black squares arranged in a grid of 36 contiguous. The region tested extended laterally to $-14^\circ 50'$ and superiorly/inferiorly to $\pm 7^\circ$. Greater than 92 % correct performance on all right visual field stimulus presentations indicates that TAB was able to correctly perform this task. As with clinical perimetry, we reliably demonstrated sparing of vision parafoveally within the field defect. Within the superior visual field, detection occurred for stimuli extending 3°10' into the field defect; in the inferior field detection abilities extended 8° into the field defect. No islands of residual vision were found, and thus microperimetry was not performed.

In the absence of islands of vision, four locations within the field defect were selected for assessing TAB's saccadic localization abilities: (Up-far = -9° , 5.8°; Down-far = -9° , -5.8° ; Up-close = -4.3° , 3.5°; Down-close = -4.3° , -3.5°). Additionally with TAB a stimulus was presented within his seeing field at 2.5°, 0°. Perfect performance ($n = 48$) for the seeing field location demonstrates TAB's understanding of the task. TAB exhibited above chance performance within his blind field at one of the four locations: Down-close. This is located within his area of spared phenomenal vision, as assessed by stabilized mapping. Performance at the other blind field locations did not differ from chance. TAB declined to proceed with the other testing sessions.

4. Discussion and conclusion

The aim of these studies was to explore the variability of residual visual abilities following damage to primary visual cortex. We reasoned that documenting a pattern of within and between subject variability would allow us to differentiate between the various neural substrates deemed responsible for mediating blindsight.

We tested seven subjects who had extensive visual field defects due to damage of the occipital cortex. As summa-

TABLE 1. Summary of results. For each subject, visual field tested, and residual abilities demonstrated (✓) or not (X), are indicated

ID	Visual Field	Island(s) of Detection	Localization Saccadic/Verbal	Wavelength Discrimination	Shape Discrimination	Motion Detection
CLT:	left	✓	X/X	✓	✓	X
CN:	left	X	—/—	—	—	—
EH:	right	X	X/X	X	X	X
FN:	left	✓	✓/✓	X	X	✓
FS:	right	✓	—/—	—	—	—
JC:	left	✓	✓/X	✓	X	X
TAB:	left	X	X/—	—	—	—

Note: Abilities not tested are denoted by a '—' symbol.

ized in Table 1, the general pattern of results demonstrates considerable between and within subject variability. Four of these subjects possess isolated areas of residual detection (CLT, FN, FS, and JC). Micromapping was employed to further define the spatial limits of these areas. One island of detection found within FN's superior visual field using 2.33° stimuli was not evident with the smaller 70' stimuli employed with micromapping. This suggests that isolated areas of detection may only be evident when large retinal areas are stimulated. Within these islands, two demonstrated localization abilities (FN and JC), two demonstrated wavelength discrimination abilities (CLT and JC), one demonstrated motion detection (FN) and one demonstrated the ability to discriminate between a small, but not a large, square or diamond (CLT). This ability to discriminate small but not large stimuli seems counterintuitive. However, when considered in conjunction with micromapping, it further supports the notion that CLT's island is relatively restricted in size (< 2°). One explanation is that the small stimulus provides differential contour or pattern information within the island, but the large stimulus, by blanketing the island, does not.

Simply put: different subjects have different abilities at different locations. This between and within subject variability is inconsistent with a retinotectal pathway explanation of blindsight, which predicts an orderly distribution of abilities throughout the visual field. Dissociating a geniculostriate from a spared striate explanation is more difficult since both predict within and between subject variability. The main difference is that an explanation based on spared striate cortex predicts abilities will be clustered, as if funneled through a common retinotopically organized stage. An explanation based on geniculostriate projections does not necessarily predict that residual abilities will be funneled, so that different abilities may be found at different locations. Within our subjects we primarily found abilities clustered at islands of detection. Occasionally localization abilities, in addition to being clustered at islands of detection, were also found at non-island locations. However, it is noteworthy, that any residual abilities NOT clustered at islands were also NOT demonstrated elsewhere – or put another way – if residual abilities were found, they were clustered at an island of detection and occa-

sionally at other locations within the blind field. In addition to these islands of vision, all subjects had remnants of spared visual cortex (see Figs 1B, 2B, 3B, and 4B). Thus, the islands behavioral sparing taken in conjunction with the remnants of cortical sparing are most consistent with the notion that blindsight is mediated by spared, albeit dysfunctional, remnants of the primary visual pathway.

Of course, the current results do not preclude an explanation based on secondary pathway mediation in other cases of blindsight. It is noteworthy that additional reports of patchiness of residual vision, with [19] and without [31] awareness, have interpreted their results as consistent with explanations based on remnants of spared striate cortex. Conversely, another recent report of variability of residual vision within a field defect has been interpreted as further support for an explanation based on secondary visual system mediation, though it clearly reports that blindsight is not demonstrable throughout the subject's field defect [21]. In sum, an important implication of these data is that patchy demonstrations of blindsight are most consistent with explanations based on remnants of the primary visual pathway.

References

- [1] Barbur, J.L., Forsythe, P.M. and Findlay, J.M. Human saccadic eye movements in the absence of the geniculocalcarine projection. *Brain* **111** (1988) 83–82.
- [2] Barbur, J.L., Ruddock, K.H. and Waterfield, V.A. Human visual responses in the absence of the geniculocalcarine projection. *Brain* **103** (1980) 905–928.
- [3] Barbur, J.L., Watson, J.D., Frackowia, R.S. and Zeki, S. Conscious visual perception without V1. *Brain* **116** (1993) 1293–1302.
- [4] Bender, M.B. and Kreiger, H.P. Visual function in perimetrically blind fields. *Archives of Neurology and Psychiatry* **65** (1951) 72–79.
- [5] Blythe, I.M., Bromely, J.M., Kennard, C. and Ruddock, K.H. Visual discrimination of target displacement remains after damage to the striate cortex in humans. *Nature* **320** (1986) 619–621.
- [6] Blythe, I.M., Kennard, C. and Ruddock, K.H. Residual vision in patients with retrogeniculate lesions of the visual pathways. *Brain* **110** (1987) 887–905.
- [7] Campion, J., Latt, R. and Smith, Y.M. Is blindsight an effect of scattered light, spared cortex and near-threshold vision? *The Behavioral and Brain Sciences* **6** (1983) 423–486.

- [8] Celesia, G.G., Bushnell, D., Cone Toileikis, S. and Brigell, M.G. Cortical blindness and residual vision: is the "second" visual system in humans capable of more than rudimentary perception. *Neurology* **41** (1991) 862–869.
- [9] Cowey, A. and Stoerig, P. The neurobiology of blindsight. *Trends in Neurosciences* **14** (1991) 140–145.
- [10] Cowey, A., Stoerig, P. and Perry, V.H. Transneuronal retrograde degeneration of retinal ganglion cells after damage to striate cortex in macaque monkeys: selective loss of p beta cells. *Neuroscience* **29** (1989) 65–80.
- [11] Crane, H.D. and Clark, M.R. Three-dimensional visual stimulus deflector. *Applied Optics* **17** (1978) 706–714.
- [12] Crane, H.D. and Steele, C.M. Accurate three-dimensional eyetracker. *Applied Optics* **17** (1978) 691–705.
- [13] Felleman, D.J. and Van Essen, D.C. Distributed hierarchical processing in the primate cerebral cortex. *Cerebral Cortex* **1** (1991) 1–47.
- [14] Fendrich, R., Wessinger, C.M. and Gazzaniga, M.S. Residual vision in a scotoma: implications for blindsight. *Science* **258** (1992) 1489–1491.
- [15] Hess, R.F. and Pointer, J.S. Spatial and temporal contrast sensitivity in hemianopia: a comparative study of the sighted and blind hemifields. *Brain* **112** (1989) 871–894.
- [16] Holmes, G. Disturbances of vision by cerebral lesions. *British Journal of Ophthalmology* **2** (1918) 353–384.
- [17] Holtzman J.D. Interactions Between cortical and subcortical visual areas: evidence from human commissurotomy patients. *Vision Research* **24** (1984) 801–813.
- [18] Horton, J.C. and Hoyt, W.F. The Representation of the Visual Field in Human Striate Cortex. *Archives of Ophthalmology* **109** (1991) 816–824.
- [19] Kasten, E. and Sabel, B.A. Visual field enlargement after computer training in brain damaged patients with homonymous deficits: an open pilot trial. *Restorative Neurology and Neuroscience* **8** (1995) 113–127.
- [20] Kasten, E., Wüst, S., Behrens-Baumann, W. and Sabel, B.A. Computer-Based Training for the Treatment of Partial Blindness. *Nature Medicine* **4** (1998) 1083–1087.
- [21] Kentridge, R.W., Heywood, C.A. and Weiskrantz, L. Residual vision in multiple retinal locations within a scotoma: implications for blindsight. *Journal of Cognitive Neuroscience* **9** (1997) 191–202.
- [22] Kerkhoff, G., Münzinger, U., Haaf, E., Eberle-Strauss, G. and Stögerer, E. Rehabilitation of homonymous scotoma in patients with postgeniculate damage of the visual system: saccadic compensation training. *Restorative Neurology and Neuroscience* **4** (1992) 245–254.
- [23] Kerkhoff, G., Münzinger, U. and Meier, E.K. Neurovisual rehabilitation in cerebral blindness. *Archives of Neurology* **51** (1994) 474–481.
- [24] Livingston, M.S. and Hubel, D.H. Segregation of form, color, movement, and depth: anatomy, physiology and perception. *Science* **240** (1988) 740–749.
- [25] Macmillan, N.A. and Creelman, C.D. Detection theory. Cambridge: Cambridge University Press, 1991.
- [26] Marzi, C.A., Tassinari, G., Aglioti, S. and Lutzemberger, L. Spatial summation across the vertical meridian in hemianopsics: a test of blindsight. *Neuropsychologia* **24** (1986) 749–758.
- [27] Matin, L. and Mackinnon, G.E. Autokinetic movement: selective manipulation of directional components by image stabilization. *Science* **143** (1964) 147–148.
- [28] Pöppel, E., Held, R. and Frost, D. Residual visual functions after brain wounds involving the central visual pathways in man. *Nature* **243** (1973) 295–296.
- [29] Ptito, A., Lepore, F., Ptito, M., and Lassonde, M. Target detection and movement discrimination in the blind field of hemispherectomized patients. *Brain* **114** (1991) 497–512.
- [30] Riddoch, G. Dissociation of visual perceptions due to occipital injuries, with especial reference to appreciation of movement. *Brain* **40** (1917) 15–57.
- [31] Schräli, H., Harman, A.M. and Hogben, J.H. Blindsight in subjects with homonymous visual field defects. *Journal of Cognitive Neuroscience* (in press).
- [32] Stoerig, P. and Cowey, A. Wavelength sensitivity in blindsight. *Nature* **342** (1989) 916–918.
- [33] Stoerig, P. and Cowey, A. Wavelength discrimination in blindsight. *Brain* **115** (1992) 425–444.
- [34] Vingrys, A.J., Benes, S.C. and King-Smith, P.E. Detecting retinal lesions with automated perimetry. *Clinical and Experimental Optometry* **71** (1988) 10–29.
- [35] Wagner, B. and Boynton, R.M. Comparison of four methods of heterochromatic photometry. *Journal of the Optical Society of America* **62** (1972) 1508–1515.
- [36] Weiskrantz, L. Blindsight: a case study and implications. Oxford: Oxford University Press, 1986.
- [37] Weiskrantz, L. Residual vision in a scotoma: a follow-up study of 'form' discrimination. *Brain* **110** (1987) 77–92.
- [38] Weiskrantz, L., Harlow, A. and Barbur, J.L. Factors affecting visual sensitivity in a hemianopic Subject. *Brain* **114** (1991) 2269–2282.
- [39] Weiskrantz, L., Warrington, E.K., Sanders, M.D. and Marshall, J. Visual capacity in the hemianopic field following a restricted occipital ablation. *Brain* **97** (1974) 709–728.
- [40] Wessinger, C.M., Fendrich, R. and Gazzaniga, M.S. Islands of residual vision in hemianopic patients. *Journal of Cognitive Neuroscience* **9** (1997) 203–221.
- [41] Yukie, M. and Iwai, E. Direct projection from the dorsal lateral geniculate nucleus to the prestriate cortex in macaque monkeys. *Journal of Comparative Neurology* **201** (1981) 81–97.
- [42] Zihl, J. and von Cramon, D.Y. Visual field recovery from postchiasmatic scotoma. a review of 55 cases. *Brain* **108** (1985) 439–469.

The following publications appeared in this issue:

- [43] Berardi, N., Lodovichi, M., Caleo, M., Pizzorusso, T. and Maffei, L. Role of neurotrophins in neural plasticity: what we learn from the visual cortex. *Restor. Neurol. Neurosci.* **15** (1999) 125–136.
- [44] Chino, M.Y. The role of visual experience in the cortical topographic map reorganization following retinal lesions. *Restor. Neurol. Neurosci.* **15** (1999) 165–176.
- [45] Eysel, U.T., Schweigart G., Mittmann T., Eyding D., Arckens L., Qu, Y., Vandesande, F. and Orban, G. Reorganization in the visual cortex after retinal and cortical damage. *Restor. Neurol. Neurosci.* **15** (1999) 153–164.
- [46] Frost, D. Functional organization of surgically created visual circuits. *Restor. Neurol. Neurosci.* **15** (1999) 107–113.
- [47] Galuske, A.W., Kim, D.-S. and Singer, W. The role of neurotrophins in developmental cortical plasticity. *Restor. Neurol. Neurosci.* **15** (1999) 115–124.
- [48] Innocenti, G.M., Kiper, D.C., Knyazeva, M.G. and Deonna, Th.W. On nature and limits of cortical developmental plasticity after an early lesion, in a child. *Restor. Neurol. Neurosci.* **15** (1999) 219–227.
- [49] Kasten, E., Pöggel, D., Mueller-Oehring, E., Gothe, J., Schulte, T. and Sabel, B.A. Restoration of vision II: Residual functions and training-induced visual field enlargement in brain-damaged patients. *Restor. Neurol. Neurosci.* **15** (1999) 273–287.
- [50] Kerkhoff, G. Restorative and compensatory therapy approaches in cerebral blindness – a review. *Restor. Neurol. Neurosci.* **15** (1999) 255–271.
- [51] Payne, B. System-wide repercussions and adaptive plasticity: the sequelae of immature visual cortex damage. *Restor. Neurol. Neurosci.* **15** (1999) 81–106.
- [52] Sabel, B.A. Restoration of vision I: Neurobiological mechanisms of restoration and plasticity after brain damage – a review. *Restor. Neurol. Neurosci.* **15** (1999) 177–200.
- [53] Schiefer, U., Skalej, M., Dietrich, T.J. and Braun, C. Detection and follow-up of homonymous visual fields defects – perimetric essentials for evaluation of spontaneous recovery. *Restor. Neurol. Neurosci.* **15** (1999) 201–217.

- [54] Werth, R. and Moehrenschlager, M. The development of visual functions in cerebrally blind children during a systematic visual field training. *Restor. Neurol. Neurosci.* **15** (1999) 229–241.
- [55] Wörgötter, F., Suder, K. and Funke, K. The dynamic spatio-temporal behavior of visual responses in thalamus and cortex. *Restor. Neurol. Neurosci.* **15** (1999) 137–152.

Copyright of Restorative Neurology & Neuroscience is the property of IOS Press and its content may not be copied or emailed to multiple sites or posted to a listserv without the copyright holder's express written permission. However, users may print, download, or email articles for individual use.